

Chronic Wound Debridement in an Acute Setting to Facilitate Improved Management Objectives Utilising Bioactive Microfibre Gelling (BMG™) Technology

Author: Danielle Blake, Fundamentals of Care Lead Nurse / Tissue Viability Sister, Barking Havering and Redbridge University Hospitals, UK
Aline Lopes, Lead Tissue Viability Nurse, Barking Havering and Redbridge University Hospitals, UK

Aim

All wounds can be serious, have a negative impact on individuals, their families and healthcare services. Wounds often contain necrotic or sloughy tissue, which can harbour bacteria and biofilm acting as a barrier to healing. Debridement is an integral part of wound management.

In 2023 the Tissue Viability Team was presented with the opportunity to evaluate a 100% pure Chitosan dressing, derived from chitin, with Bioactive Microfibre Gelling (BMG™) Technology. Studies have found chitosan to have several properties that aid wound healing (Dai Tet al 2011).

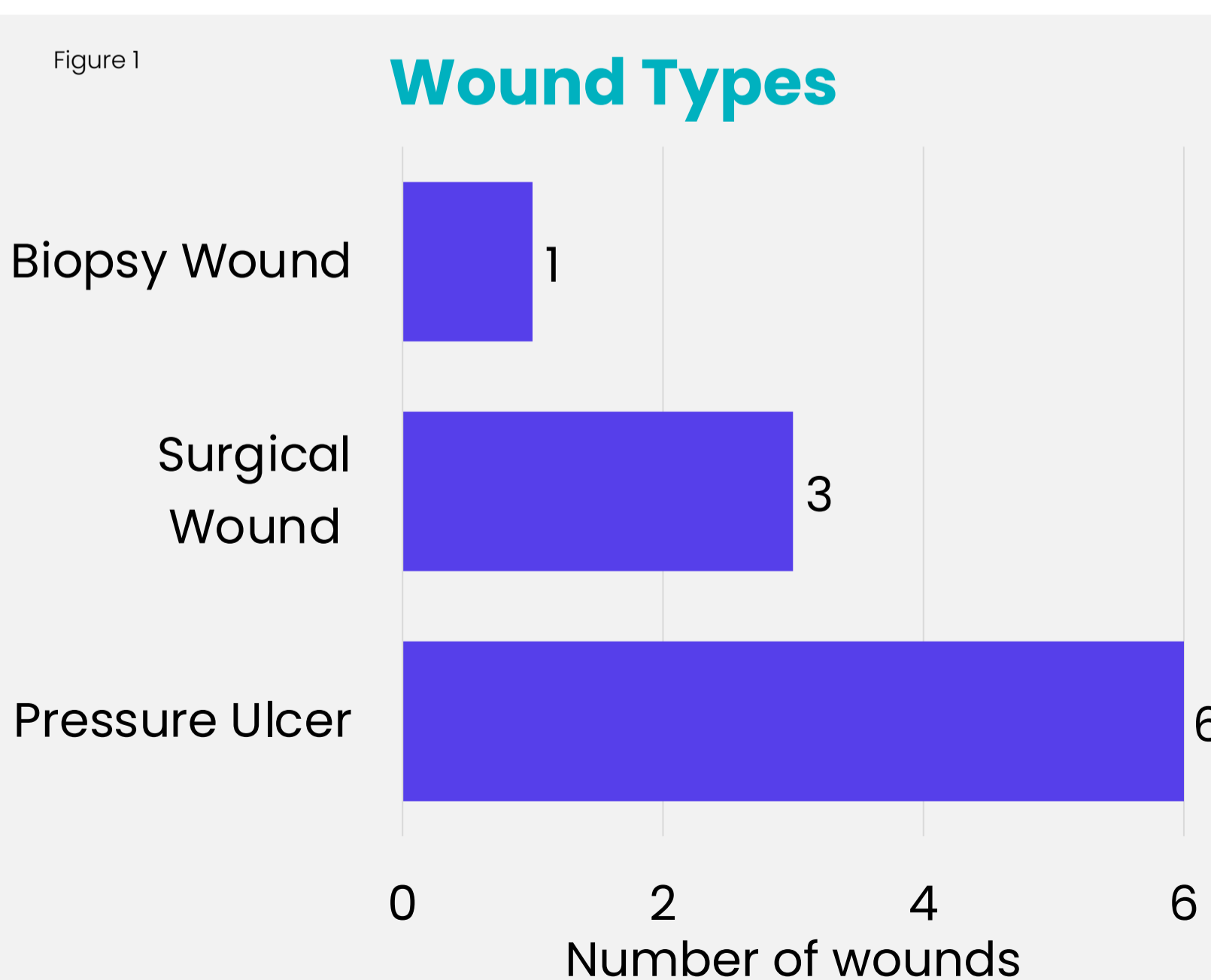
The aim of this study was to investigate the potential for autolytic debridement using the BMG technology dressing, to facilitate wound healing.

Method

Evaluation of 10 inpatient case studies over a 2-week period in the acute setting. The average patient age was 78 years old. 70% female, 30% male.

Wound types included: Pressure ulcer (6) Surgical wound (3) Biopsy wound (1) (Figure 1).

At initial assessment, 50% of wounds were identified as 'deteriorating', 40% as 'static', and only 10% as 'progressing.'



Results

In 8 cases there was a visible reduction in devitalised tissue, decrease in wound size and improvement of the wound bed. Within just 2 weeks there was a significant improvement in average wound bed condition, with slough reducing from 85% to 36.25%, and granulation tissue increasing from 14% to 63.12% (Figure 2).

A noticeable decrease in signs of infection was observed and odour eliminated due to the dressing's antibacterial anti biofilm properties.

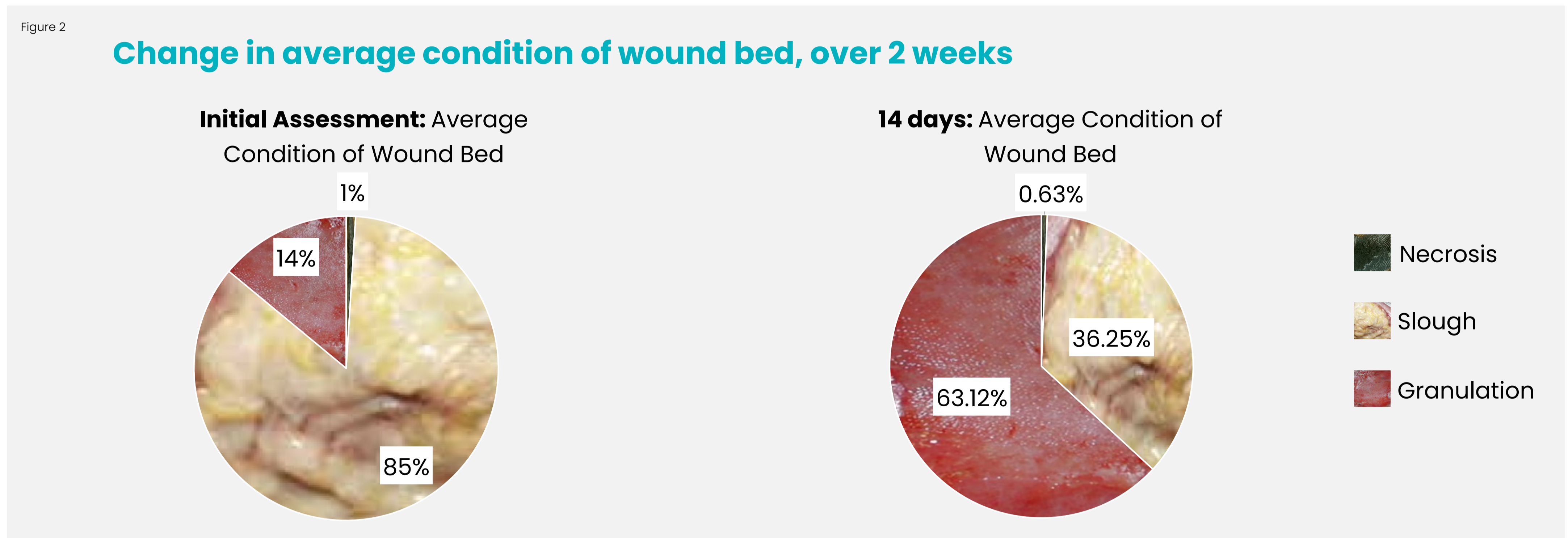
In one patient the use of the BMG dressing facilitated earlier application of Negative Pressure Wound Therapy (NPWT) after one week due to improved wound bed status.

Conclusion

Within just two weeks, the BMG dressing demonstrated an effective option for wound debridement, facilitating the maintenance of a healthy wound bed.

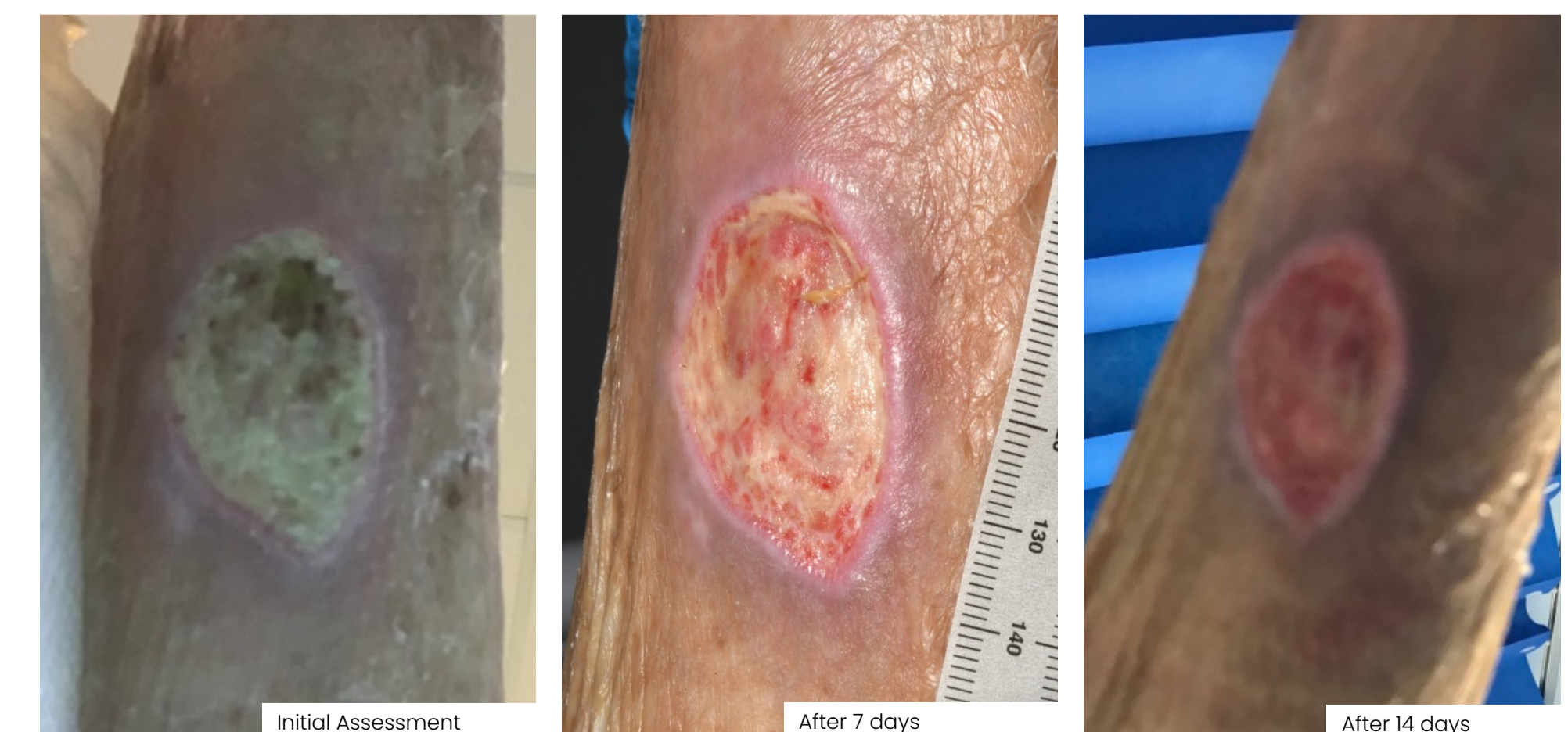Early and appropriate wound debridement facilitates healing, reduces infection risk, and improves patients' quality of life.

To find out more scan the QR code:



Case Study: Pressure Ulcer

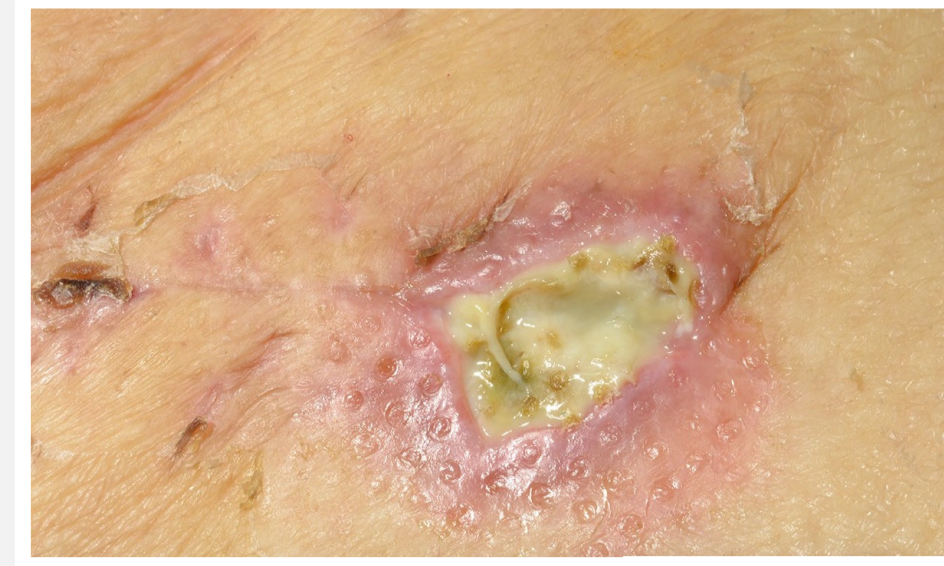- 82-year-old male with a pressure ulcer, of several months' duration.
- Initial assessment:** wound was static, with 100% slough, measuring 4cm x 3.5cm.
- Treatment objectives:** autolytic debridement of wound bed.
- Within 7 days:** slough reduced to 50% and granulation increased to 50%.
- Within 14 days:** slough reduced to 5% and granulation increased to 95% .
- Treatment objectives achieved.
- Patient discharged with improved wound healing



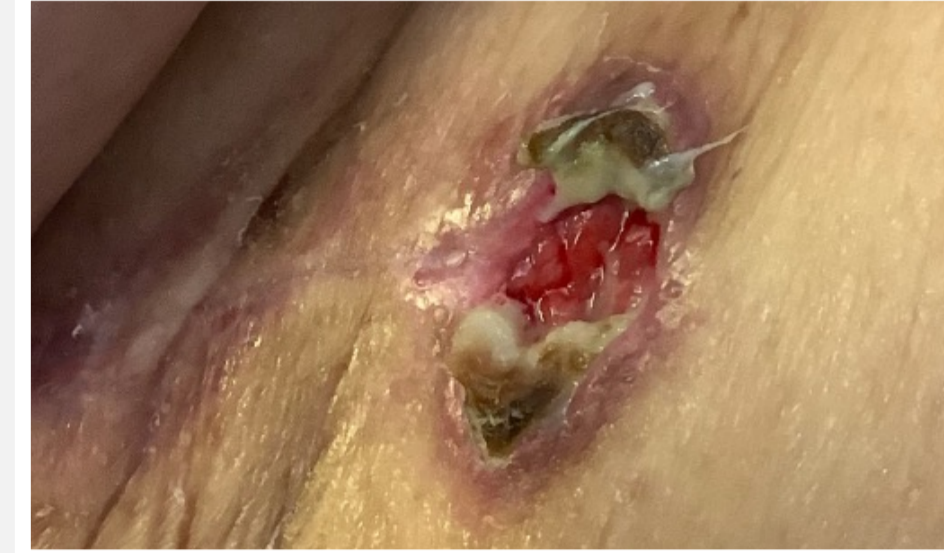Case studies demonstrating autolytic debridement and promotion of wound healing over a 14-day period

Case Study: Surgical Wound

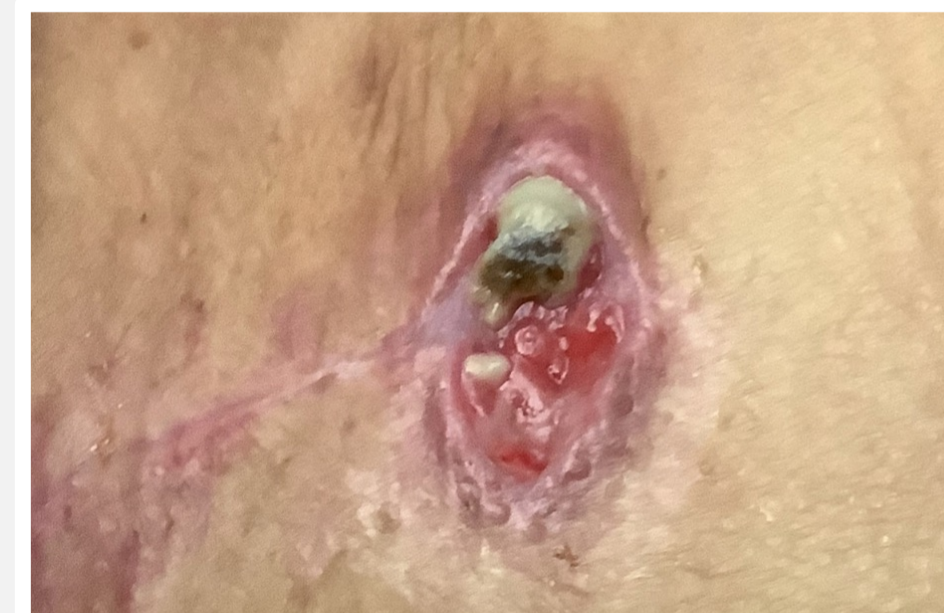- 91-year-old female with surgical wound to right thigh following open reduction and internal fixation.
- Initial assessment:** wound was deteriorating, measuring 2cm x 2cm with 100% slough to wound bed.
- Treatment objectives:** autolytic debridement and promotion of healing.
- Within 7 days:** slough reduced to 50% and granulation increased to 50%.
- Within 14 days:** slough reduced to 40% and granulation increased to 60%.
- Treatment objectives achieved. Wound healed prior to discharge.



Initial Assessment



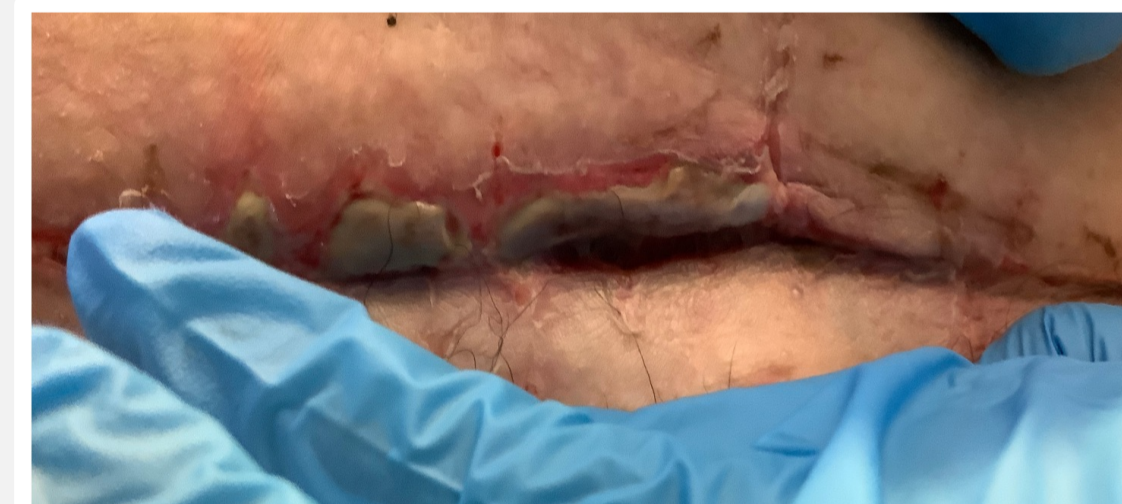After 7 days



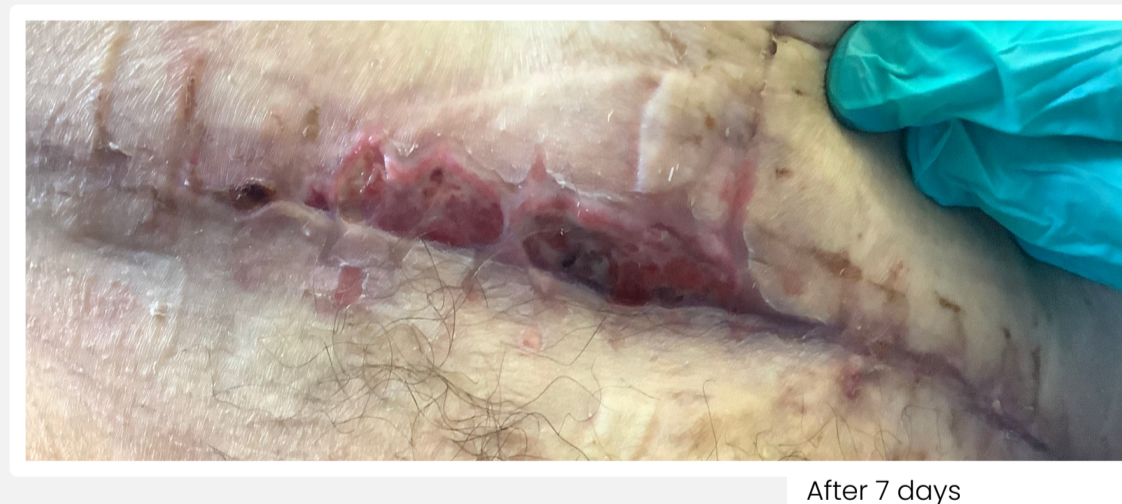After 14 days

Case Study: Dehisced Surgical Wound

- 51-year-old female with surgical wound to abdomen elective total hysterectomy complicated by massive haemorrhage. 1 month duration on presentation.
- Initial assessment:** wound was deteriorating, with 100% slough to wound bed, measuring 12cm x 1cm. Periwound skin was macerated.
- Treatment objectives:** autolytic debridement of wound bed.
- Within 7 days:** slough reduced to 0% and granulation increased to 100%.
- Treatment objectives achieved within 7 days, allowing application of Negative Pressure Wound Therapy.



Initial Assessment



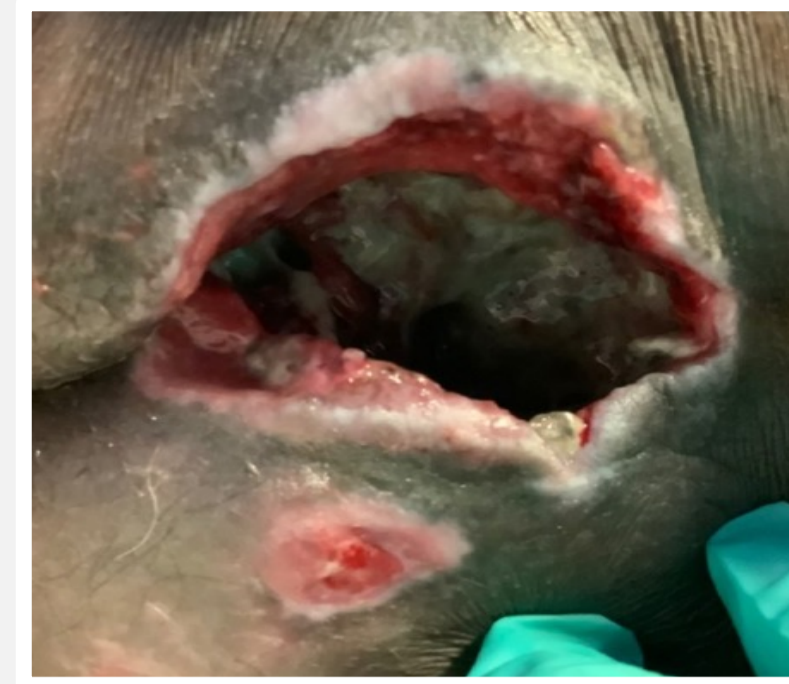After 7 days



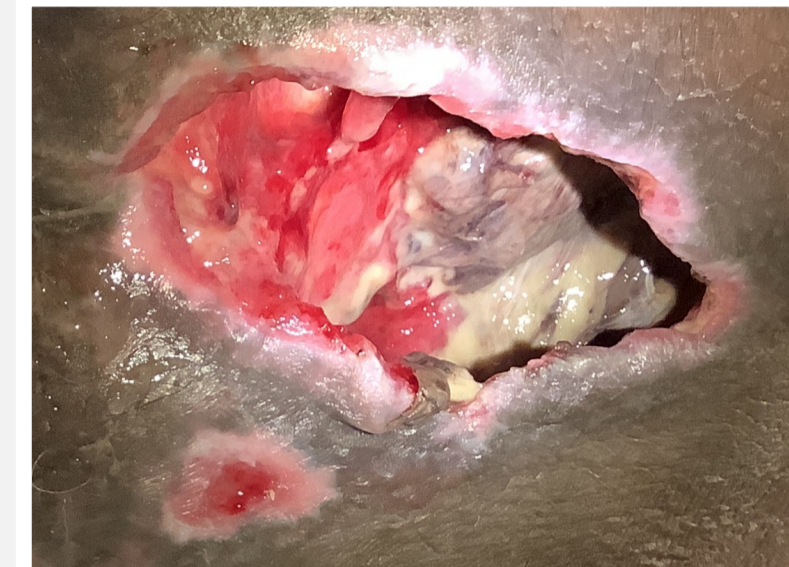After 14 days

Case Study: Pressure Ulcer

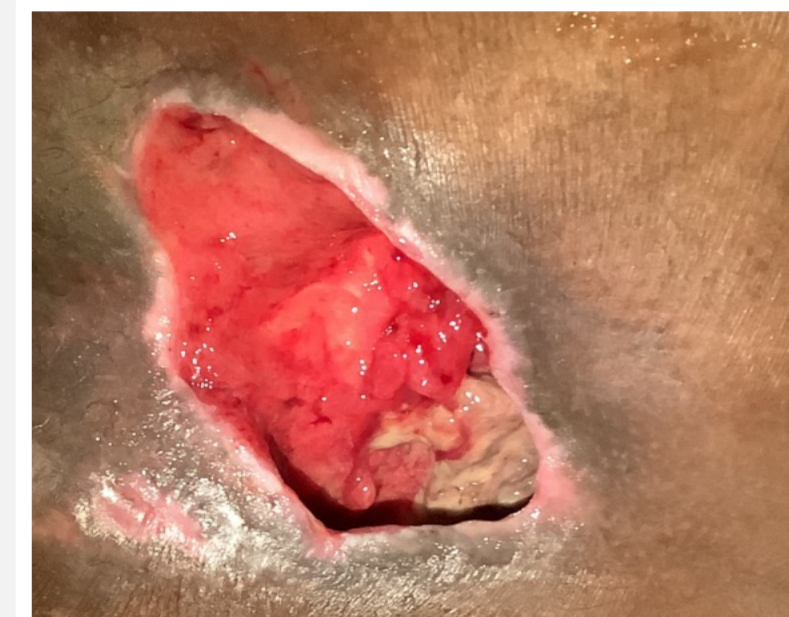- 62-year-old female with a history of stroke. Category 4 pressure ulcer to sacrum, of 2 months duration.
- Initial assessment:** wound was deteriorating with 90% slough and 10% granulation, measuring 10cm x 10cm x 10cm. Osteomyelitis present. Periwound skin was macerated due to high levels of exudate. Patient pain level of 9.
- Treatment objectives:** autolytic debridement, management of exudate and promotion of healing.
- Within 7 days:** slough reduced to 30% and granulation increased to 70%. Patient pain level reduced from 9 to 7.
- Within 14 days:** slough remained at 30% and granulation at 70%. Periwound skin improved to healthy.
- Clinicians noted a "big difference when changing from silver dressing. After 1 week of application, reduced sloughy tissue. Appears healthier."



Initial Assessment



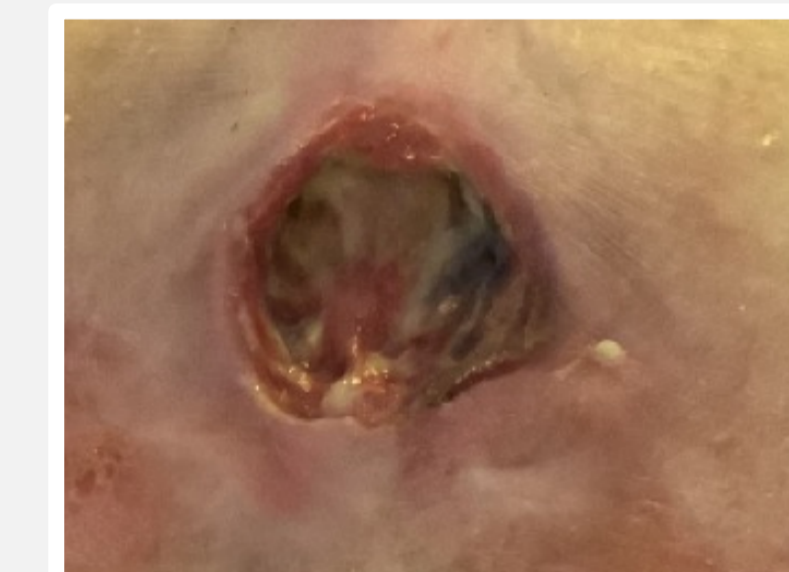After 7 days



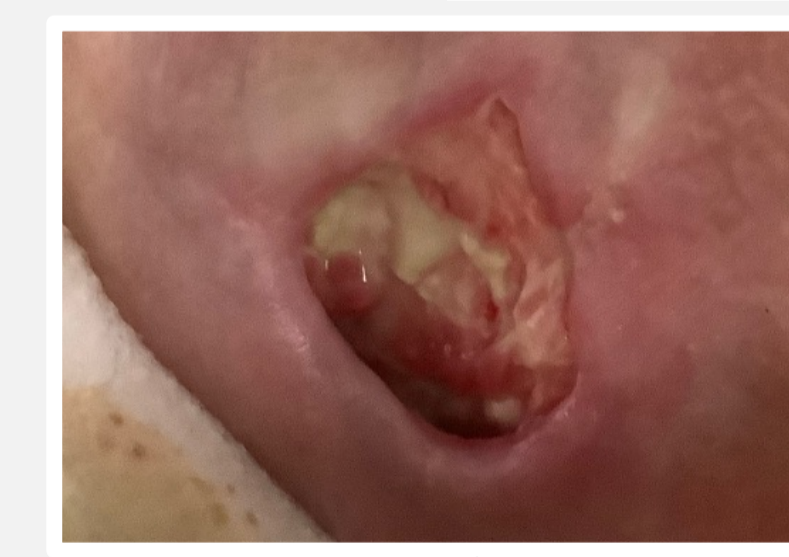After 14 days

Case Study: Pressure Ulcer

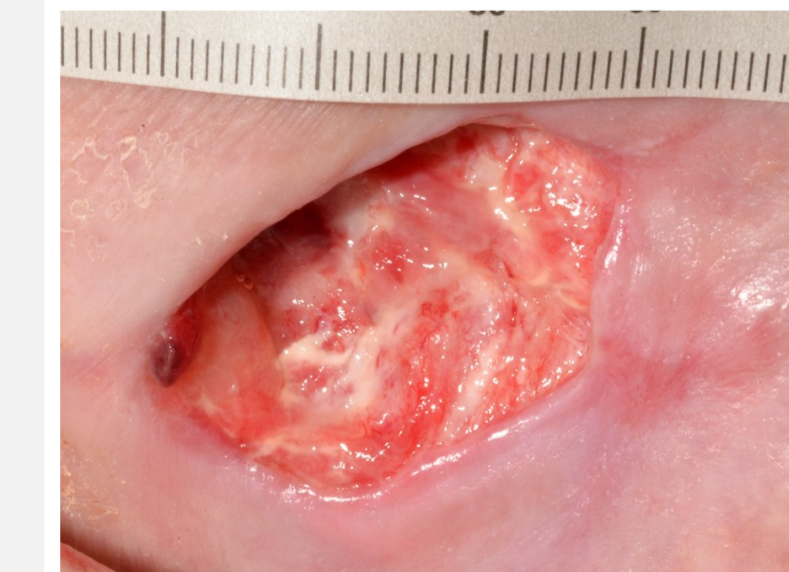- 83-year-old female with a category 4 pressure ulcer to sacrum, of unknown duration.
- Initial assessment:** wound was static, with 90% slough and 10% granulation to wound bed, measuring 4cm x 4cm with unknown depth. Suspected osteomyelitis. Periwound skin was inflamed with erythema.
- Treatment objectives:** autolytic debridement and promotion of healing.
- Within 7 days:** slough reduced to 50% and granulation increased to 50%. Periwound skin condition improved.
- Within 14 days:** slough reduced to 10% and granulation increased to 90%.
- Treatment objectives achieved. Within 2 weeks, patient pain level reduced from 8 to 5, increasing patient comfort. Periwound skin improved from inflamed to healthy.



Initial Assessment



After 7 days



After 14 days