

A Case Study on the Effectiveness of a Chitosan Lactate Microfibre Dressing in Managing Hyper-granulation Tissue in a Chronic Second-degree Burn.

Authors:

Ana Raquel Alves, Head Nurse, UCCI da Associação Solidariedade Social Alto Paiva - Vila Nova de Paiva, Avenida 25 de Abril - 3650-209. Email: anaralves@hotmail.com Tel: +351 966652238
Mónica Sofia Marques, Registered Nurse, UCCI da Associação Solidariedade Social Alto Paiva - Vila Nova de Paiva, Avenida 25 de Abril - 3650-209. Email: monicasofiamarques@sapo.pt

AIM

To evaluate the impact of a chitosan lactate gelling fibre dressing (MaxioCel®) on the management of a hyper-granulating chronic second-degree (partial thickness) burn wound in a paraplegic patient with a history of non-responsiveness to conventional treatment modalities.

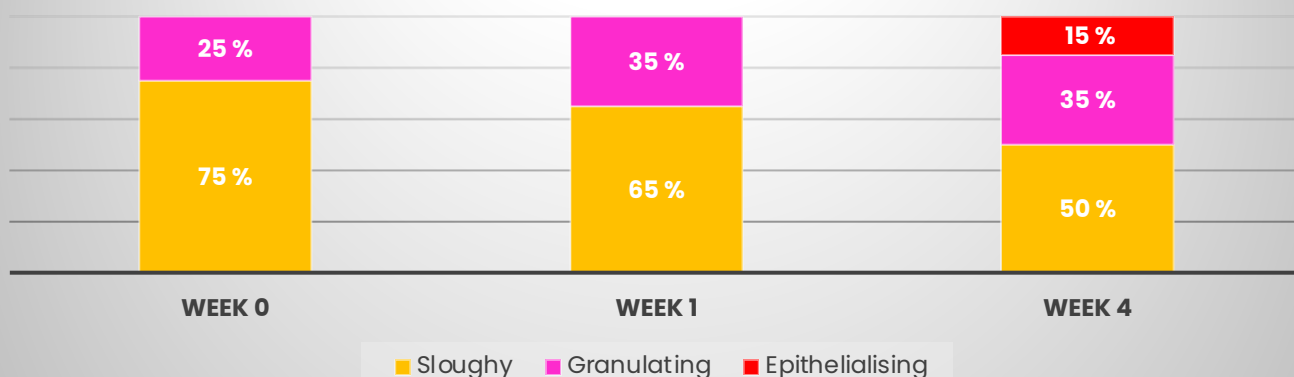
METHOD

Following standard care protocols and with informed consent, MaxioCel was applied by nursing staff to a deteriorating chronic second-degree burn wound on the right lower limb of a patient. The wound had a 9-year duration and was previously managed with traditional dressings. The study focused on observing changes in the hyper-granulation, tissue types, exudate levels, and patient comfort over a 4-week period.

RESULTS

MaxioCel demonstrated a significant reduction in hyper-granulation tissue which decreased by more than 50%, wound size reduced from 40x15 cm to 30x15 cm, with a marked increase in healthy granulation and epithelialisation. The patient reported greater comfort and improved emotional well-being. The dressing's effective exudate management properties facilitated the transfer of the patient from the bed to a chair, an essential stage in his rehabilitation.

Condition of Wound Bed in 3 stages



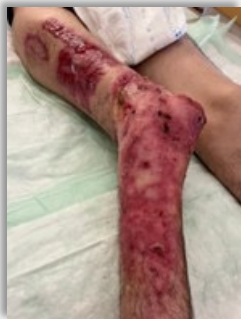CONCLUSION

The application of MaxioCel resulted in substantial clinical improvement of a complex, longstanding second-degree burn wound. The dressing promoted effective wound management by reducing hyper-granulation, controlling exudate, and facilitating autolytic debridement.

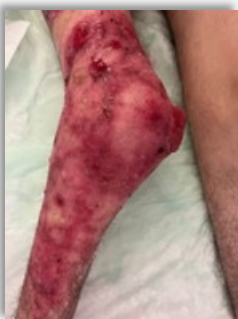The exact cause of hyper-granulation tissue is poorly understood and referenced as multifaceted. This case suggests the potential of MaxioCel to address some of those causes and potentially be a valuable addition to wound care regimens, particularly for patients with challenging non-healing wounds.

CASE STUDY

BEFORE



22.06.2023



22.06.2023

This case study on a 27-year-old male patient with a chronic right limb wound, originating from a second-degree hot water burn injury. Medical history included brain injury, paraplegia and anaemia.

The wound, present since 2014, was assessed and classified as deteriorating and hyper-granular, with 75% slough and 25% granulation, and measured 40cm x 15cm with high exudate levels but no pain. Previous dressing regimes included a hydrofibre (Aquacel® Ag) silicone contact layer (Mepitel®), iodine and paraffin gauze.

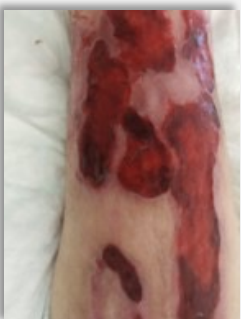The treatment strategy employed MaxioCel to protect granulation tissue, control exudate, promote autolytic debridement, and encourage healing. Dressings were carried out every 3 days.

Over the treatment period, the wound condition improved, indicated by reduced hyper-granulation tissue, a decrease in slough by 50%, and an increase in granulation and epithelialisation. The wound's length decreased by 10cm suggesting a positive response to MaxioCel, which was continued.

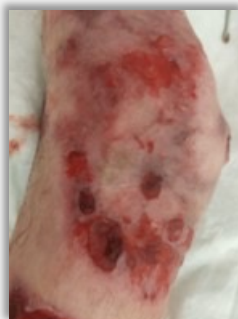The new dressing regime helped to facilitate the transfer of the patient from the bed to a chair and the patients emotional well-being was enhanced significantly as a result.

The clinicians noted MaxioCel's benefits and expressed intentions to continue its use and recommend to other healthcare professionals due to its effectiveness.

AFTER



22.07.2023



22.07.2023

Key Clinical Benefits

1

Effective Hyper-granulation

Management: MaxioCel significantly reduced hyper-granulation tissue by more than 50%, indicating its effectiveness in managing an over-granulating wound.

2

Enhanced Granulation, Epithelialisation, and Exudate Management

Management: MaxioCel increased healthy granulation tissue and epithelialisation, crucial for wound closure. Effectively controlled exudate levels, maintaining an optimal wound moisture balance conducive to healing.

Key Patient Benefits

1

Increased Comfort: The patient reported greater comfort during the treatment period, which is an important aspect of patient-centred care.

2

Emotional Well-being: The new dressing regime facilitated easy dressing changes and the patient's emotional state improved.

3

Rehabilitation: MaxioCel's management of the wound exudate assisted patient to transfer from bed to chair, an essential stage for rehabilitation.